

## Platelet-Rich Plasma Combined With Skin Substitute for Chronic Wound Healing: A Case Report

Rebecca L. Knox, CCP; Allen R. Hunt, CCP; John C. Collins, CCP; Marie DeSmet, RN;  
Sara Barnes, DO

Trinity Center for Wound Care and Hyperbaric Medicine, Bettendorf, Iowa

**Abstract:** Contemporary management of chronic wounds focuses on improving natural healing and individualization of treatment. Incorporating multiple therapies has become increasingly common. Of interest are autologous growth factors, which are especially important in chronic wound healing and may contribute to tissue formation and epithelialization. Autologous platelet concentrate or platelet-rich plasma (PRP) is a concentration of at least five autologous growth factors and has been shown to accelerate wound healing and may have infection-fighting properties. Chronic wound healing is complicated by both decreased growth factor availability and infection, making PRP use valuable in these types of wounds. In this report, the use of PRP therapy alone and in combination with a bioengineered skin substitute as a platelet-rich tissue graft in a chronic, non-healing

wound is detailed. Over 27 weeks, the patient received multiple therapies in attempts to heal a severe decubitus ulcer of the sacrum. The introduction of PRP therapy at Week 14 led to a 26% reduction in wound depth over 4 weeks. At Week 19, PRP therapy was combined with a powdered skin substitute to create a platelet-rich tissue graft. The combination brought dramatic results, eliminating wound tunneling and reducing the wound dimensions from 6.2 cm long × 6.7 cm wide × 2.7 cm deep to 5.0 cm long × 6.0 cm wide × 1.4 cm deep. The promising observations from this case report indicate that further study on the combining of PRP therapy and skin substitutes is necessary. **Keywords:** platelet-rich plasma, chronic wounds, growth factors, skin substitutes, infection. *JECT. 2006;38:260–264*

Wound healing is a complex process characterized by stages of inflammation, proliferation, repair, and remodeling (1,2). The inflammatory stage of healing is initiated in part by platelet degranulation (1). Platelets contain at least five growth factors that may contribute to tissue formation and epithelialization: platelet-derived growth factor (PDGF), platelet factor 4, transforming growth factor- $\beta$ , platelet-derived angiogenesis factor, and platelet-derived epidermal growth factor (1,3). On their release, these factors stimulate and modulate multiple biological processes that are important in wound healing (1–4). Chronic wounds may, in some cases, lack growth factors (2). Decreased growth factor availability may be a result of decreased production, decreased release, trapping, excess degradation, or a combination of these mechanisms (2).

Recent studies have found that autologous platelet concentrate with growth factors (APGF) or platelet-rich

plasma (PRP) may accelerate wound healing (2,4–6). Margolis et al. (6) showed increased wound healing with APGF in >6000 patients, with the effect being greatest in those with the most severe wounds. There is also indication that PRP has infection-fighting properties. PRP has been shown to reduce the incidence of sternal infection (7), and it is now understood that platelets play a role in recruiting white blood cells (8) and release bactericidal factors (9). These revelations make PRP use in chronic wounds all the more attractive, because they are plagued by infection.

Contemporary management of chronic wounds is geared toward improving natural healing (10). PRP therapy can be part of a multi-faceted approach, which may incorporate hyperbaric oxygen, electrical stimulation, skin surface negative pressure, exogenous growth factors, and bioengineered skin substitutes. Bioengineered skin substitutes have emerged over the past 20 years and are widely used to treat chronic wounds (10). For such wounds, the goal of skin substitute therapy is to provide a temporary biologic dressing that accelerates skin tissue regeneration and wound healing by stimulating the patient's own wound bed-derived skin cells (10). The available skin substitutes vary in terms of cell source, tissue

Address correspondence to: Rebecca L. Knox, Trinity Medical Center, WOR 2701 17th Street Rock Island, IL 61201. E-mail: rebeccaahlgren@hotmail.com

The senior author has stated that authors have reported no material, financial, or other relationship with any healthcare-related business or other entity whose products or services are discussed in the paper.

differentiation-inducing substance, and matrix, but most consist of sheets of biomaterial matrix containing allogenic cells (10).

Matrices in sheet form do not lend themselves to use in irregular wounds with tunneling or extensions into deep soft tissue. Recently, a powdered form of matrix has been developed. Graft Jacket Xpress Flowable Soft Tissue Scaffold (Wright Medical Technology, Arlington, TN) is a micronized human tissue allograft intended for homologous use in the repair of damaged or inadequate integumental tissue. The allograft serves as a three-dimensional framework to support soft tissue regeneration and angiogenesis. Graft Jacket Xpress is applied by syringe through an 18-gauge, flexible catheter, making it ideal for wounds exhibiting tunneling.

In a pilot series of six diabetic patients presenting with chronic foot ulcers, the use of the Graft Jacket Xpress led to complete depth filling within 2 weeks for five of six patients (D. Armstrong and S. Brigido, unpublished data). In addition, the sheet form of the Graft Jacket Matrix has shown a 38.9% higher closure rate vs. control for full-thickness chronic wounds in a prospective, randomized clinical trial (11). The Graft Jacket Xpress and PRP therapy, alone and in combination, proved to be beneficial in treating a chronic, non-healing wound in this case.

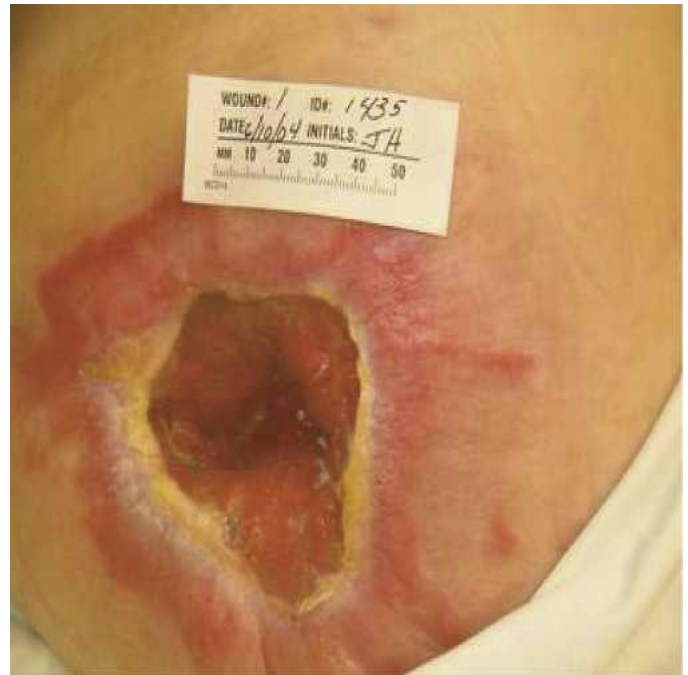## CASE REPORT

### Description

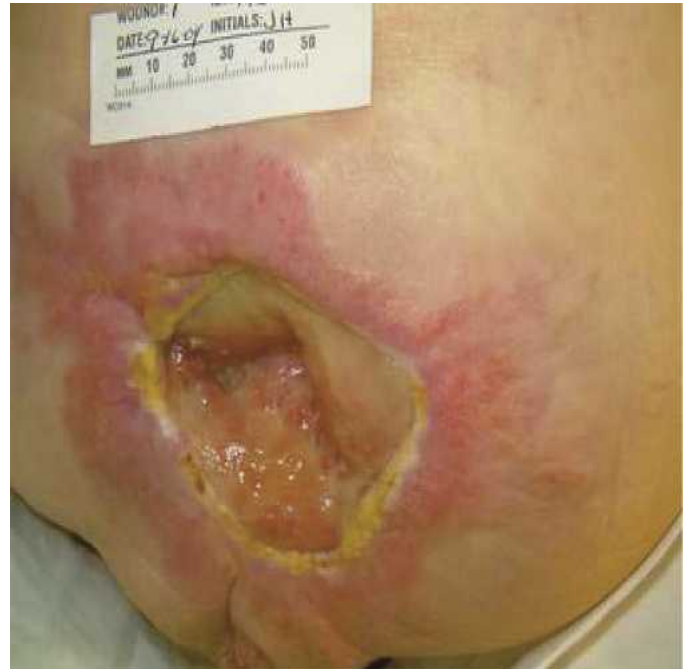The patient was a 55-year-old male T<sub>10</sub> paraplegic presenting with a chronic, non-healing decubitus ulcer of the sacrum >1 year in duration. He states the wound has persisted for 4–5 years. Previous treatment for the wound included silvadene, numerous skin flaps, Dakin's solution, and hyperbaric oxygen treatments (HBO) for necrotizing fasciitis. Immediately before coming under our care, he had a peripherally inserted central catheter (PIC line) in place to treat a methicillin resistant *Staphylococcus aureus* (MRSA) infection. At his initial visit to the wound care clinic, the wound measured 7.5 cm long × 7.5 cm wide × 4.4 cm deep (Figure 1).

Over 7 weeks, he completed 30 sessions of HBO and attended wound care clinic weekly. During this time, skin surface negative pressure therapy was used for 4 weeks, and the Graft Jacket Xpress was applied to areas of tunneling for 4 of 7 weeks. At Week 7, culture of the wound was positive for MRSA. Over the next 6 weeks, the Graft Jacket Xpress was applied to areas of tunneling 3 to 6 weeks, and standard therapy was continued. However, the wound failed to progress further. The wound now measured 6.5 cm long × 7 cm wide × 2.7 cm deep (Figure 2).

At this point, because of the severity and duration of the wound and its failure to respond to standard therapy, PRP



**Figure 1.** Week 1: wound appearance at initial wound care clinic visit. The wound is <100% epithelialized, with mild fibrin deposition and no hypergranulation. Firm, deep pink granulation tissue is present. There is erythema of the peri-wound area, and the wound margins are rolled. Rolled margins can prevent epithelialization and wound closure.



**Figure 2.** Week 14: after 13 weeks of therapy, the wound is distinctly shallower, but has made little progress over the last 6 weeks. It remains <100% epithelialized with marked fibrin deposition and no hypergranulation. There is firm, pink granulation tissue, and the wound margins are now intact, indicating reproductive epithelium.

therapy was introduced with the patient's consent. Autologous blood was obtained from the patient by venipuncture and processed with a Food and Drug Administration (FDA)-cleared device (SmartPREP; Harvest Technologies Corp., Plymouth, MA) to produce PRP and platelet-poor plasma (PPP). Using a dual liquid applicator kit (Harvest Technologies Corp.), both the PRP and PPP were activated with a mixture of bovine topical thrombin (GenTrac, Middleton, WI) and 10% calcium chloride (1000 units:1 mL) and applied to the central wound bed with the PRP being applied first. As the volume of the wound bed decreased, the volume of PRP applied decreased. After 4 weeks of PRP application, the wound measured 6.5 cm long  $\times$  7.0 cm wide  $\times$  2.0 cm deep, with tunneling measuring 0.7 cm (Figure 3).

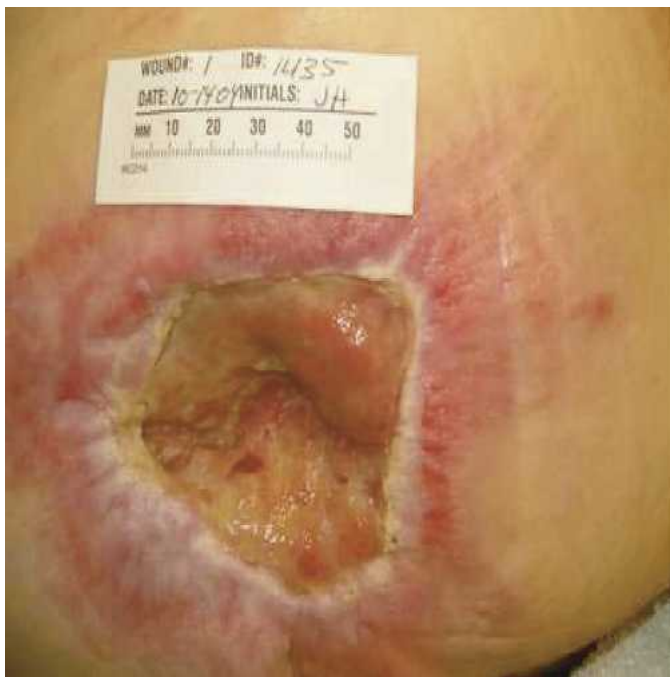After multi-disciplinary consultation, a variation on previously used therapies, which had been used to treat another chronic wound in the clinic, was introduced. With the patient's consent, PRP therapy and the Graft Jacket Xpress were combined, with the expectation that direct mixing rather than just proximity of the two therapies might enhance the effect of each. The preparation of Graft Jacket Xpress per manufacturer instructions involves rehydrating the tissue powder with 0.9% sodium chloride. The 0.9% sodium chloride was replaced with an equal amount of PRP to create a platelet-rich tissue graft, which was toothpaste-like in texture. Using the 18-gauge flexible

catheter included in the Graft Jacket Xpress kit, the platelet-rich tissue graft was injected into the tunneling area of the wound. Although the PRP in the platelet-rich tissue graft was not activated with calcium and thrombin, growth factors should have been released as the platelets were activated by contact with the powdered matrix and also by the clotting process occurring in the wound. The remaining PRP and PPP were activated and applied as previously mentioned to the central wound bed.

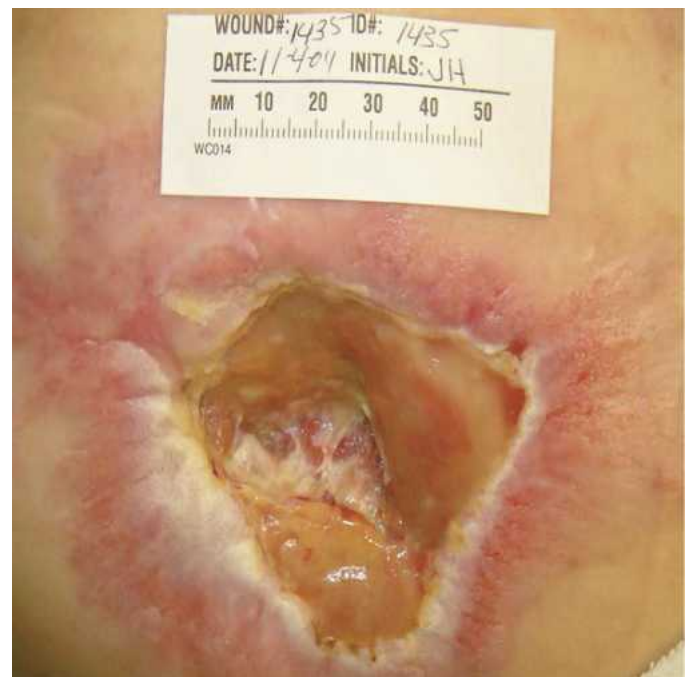After 2 weeks of the new therapy, the platelet-rich tissue graft was visibly incorporating into the wound (Figure 4). After 8 weeks, the wound had made considerable progress, measuring 5.0 cm long  $\times$  6.0 cm wide  $\times$  1.4 cm deep, with no tunneling (Figure 5). Unfortunately, at the writing of this report, the patient had developed an *E. coli* infection that hindered further healing. Platelet-rich tissue graft therapy was discontinued at this time, with PRP therapy re-instituted until the resolution of the infection.

### Observation

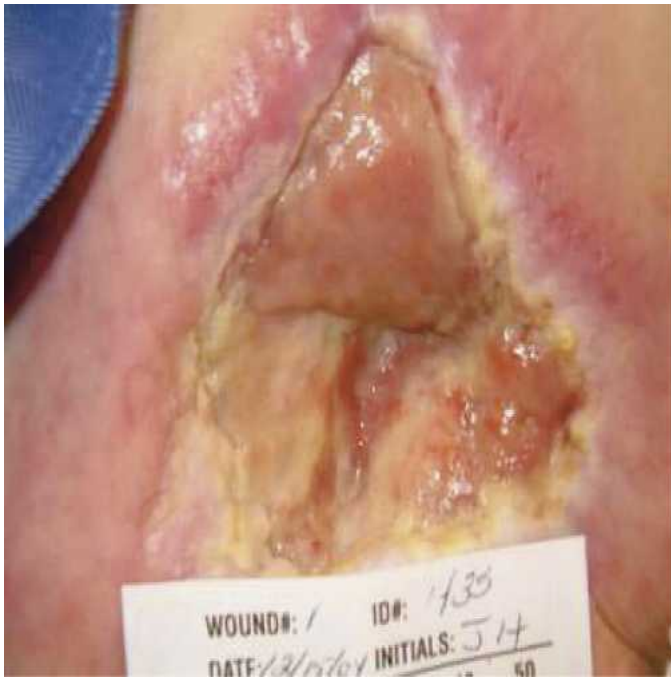Figure 6 shows the progression of the wound's dimensions over the 27 weeks of treatment documented here. During the initial 6 weeks of wound care clinic visits, the wound experienced contracture in all dimensions, with the depth decreasing drastically. At Week 7, culture of the wound was positive for MRSA, and over the next 7 weeks, healing slowed. Four weeks of PRP therapy generated a steady decline in the wound's depth, but there were no



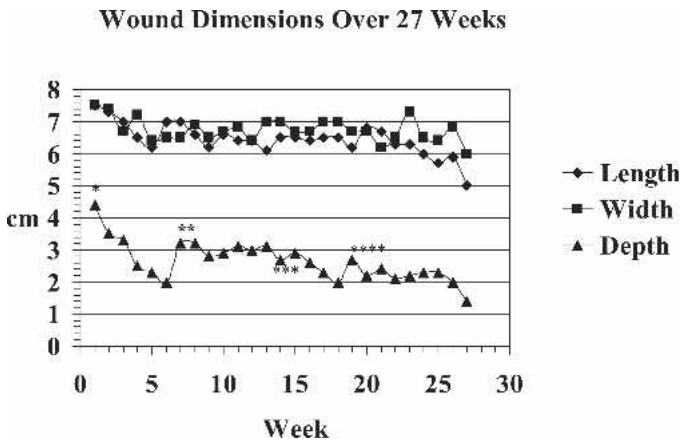
**Figure 3.** Week 18: after 4 weeks of PRP therapy, the wound depth has decreased 0.7 cm and an area of tunneling is down 0.5 cm. The wound is <100% epithelialized, with marked fibrin deposition. There is mild erythema of the peri-wound area and firm, pink granulation tissue in the wound bed.



**Figure 4.** Week 21: after 2 weeks of platelet-rich tissue graft therapy, there is minimal tunneling. The platelet-rich tissue graft is visibly incorporating into the central wound bed and is still present in the wound bed. There is <100% epithelialization and marked fibrin deposition.



**Figure 5.** Week 27: after 8 weeks of platelet-rich tissue graft therapy, there is no tunneling, and the wound depth has decreased 1.3 cm. The wound is clearly contracted in all dimensions. It continues to be <100% epithelialized, with marked fibrin deposition. The margins are intact, and there is noticeably less bleeding with debridement.



**Figure 6.** Wound dimensions over 27 weeks of treatment. \*Weeks 1–6: multiple therapies, including HBO, skin surface negative pressure, and the Graft Jacket Xpress. \*\*Weeks 7–13: MRSA at Week 7, Graft Jacket Xpress, standard therapy. \*\*\*Weeks 14–18: PRP therapy. \*\*\*\*Weeks 19–27: platelet-rich tissue graft therapy.

discernible changes in wound length or width. The decrease in depth may not have been substantial enough to incite changes in the other dimensions, because normal progression of wound healing dictates the migration of cells to the base of the wound, meaning the wound must fill in before it can contract. The introduction of the platelet-rich tissue graft therapy produced the most dramatic changes in all dimensions since the opening 6 weeks of therapy. After eight applications of platelet-rich tissue

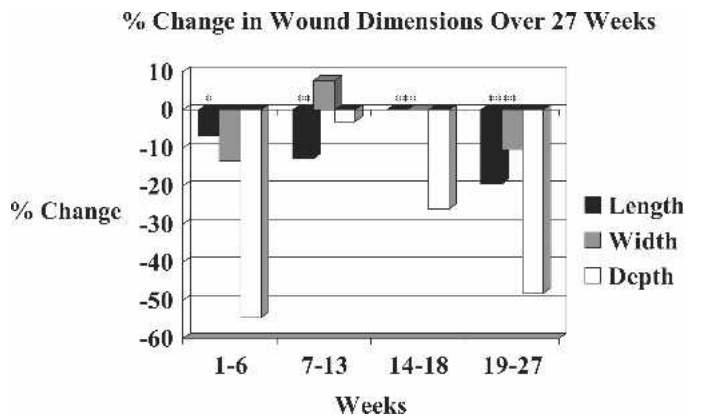
graft, the wound length had decreased 19.4%, the width 10.4%, and the depth 48% (Figure 7). Overall, the wound length was reduced 33.3%, the width was reduced 20%, and the depth was reduced 68.2%.

**DISCUSSION**

Chronic non-healing wounds present a formidable challenge and require individualized therapy to give each patient the best opportunity for wound closure.

Active intervention for these wounds, using combinations of HBO, electrical stimulation, skin surface negative pressure, bioengineered skin substitutes, and exogenous growth factors, is receiving attention in the current literature. Because PRP therapy is a concentration of platelets, it is also a concentration of at least five growth factors important in wound healing. In addition, PRP may help fight infections by recruiting white blood cells and through platelet release of bactericidal factors. For this particular wound, the combination of PRP therapy with the Graft Jacket Xpress as a platelet-rich tissue graft yielded the greatest results. Further study on the combining of PRP therapy and skin substitutes is warranted.

Much of the literature supports the use of PRP to enhance healing, but a few studies have failed to determine a benefit. Variations in devices and study designs may be responsible for negative results. Marx (12) provided a good discussion of issues leading to false-negative results and stressed that PRP should be autologous and must contain viably active platelets in sufficient concentration to aid healing. When these conditions are met, the vast majority of publications report a significant enhancement of healing when PRP is used (12). PRP therapy alone and in combination with bioengineered skin substitutes such as the Graft Jacket Xpress can be used to augment healing of intractable wounds. When used as alternative treatments



**Figure 7.** Percent change in wound dimensions over 27 weeks of treatment. \*Weeks 1–6: multiple therapies, including HBO, skin surface negative pressure, and the Graft Jacket Xpress. \*\*Weeks 7–13: MRSA at Week 7, Graft Jacket Xpress, standard therapy. \*\*\*Weeks 14–18: PRP therapy. \*\*\*\*Weeks 19–27: platelet-rich tissue graft therapy.

in a multi-faceted approach, wound closure may be an achievable goal.

## REFERENCES

1. Bennett NT, Schultz GS. Growth factors and wound healing: Part II. Role in normal and chronic wound healing. *Am J Surg.* 1993;166:74–81.
2. Crovetti G, Martinelli G, Issi M, et al. Platelet gel for healing cutaneous chronic wounds. *Transfus Apheresis Sci.* 2004;30:145–51.
3. Weed B, Davis MDP, Felty CL, et al. Autologous platelet lysate product versus placebo in patients with chronic leg ulcerations: A pilot study using a randomized, double-blind, placebo-controlled trial. *WOUNDS.* 2004;16:273–82.
4. Herouy Y, Mellios P, Bandemir E, et al. Autologous platelet-derived wound healing factor promotes angiogenesis via alphavbeta3-integrin expression in chronic wounds. *Int J Mol Med.* 2000;6:515–9.
5. Glover JL, Weingarten MS, Buchbinder DS, Poucher RL, Deitrick GA III, Fylling CP. A 4-year outcome-based retrospective study of wound healing and limb salvage in patients with chronic wounds. *Adv Wound Care.* 1997;10:33–8.
6. Margolis DJ, Kantor J, Santanna J, Strom BL, Berlin JA. Effectiveness of platelet releasate for the treatment of diabetic neuropathic foot ulcers. *Diabetes Care.* 2001;24:483–8.
7. Trowbridge C, Stammers A, Woods E, et al. Use of platelet gel and its effects on infection in cardiac surgery. *J Extra Corpor Technol.* 2005;37:381–6.
8. Lindemann S, Tolley N, Dixon D, et al. Activated platelets mediate inflammatory signaling by regulating interleukin 1B synthesis. *J Cell Biol.* 2001;3:485–90.
9. Dankert J, Krijgsveld J, van Der Werff J, Joldersma W, Zaat SA. Platelet microbicidal activity is an important defense factor against viridans streptococcal endocarditis. *J Infect Dis.* 2001;184:597–605.
10. Eisenbud D, Huang NF, Luke S, Silberklang M. Skin substitutes and wound healing: Current status and challenges. *WOUNDS.* 2004;16:2–17.
11. Brigido SA, Boc SF, Lopez RC. Effective management of major lower extremity wounds using an acellular regenerative tissue matrix: A pilot study. *Orthopedics.* 2004;27:s145–49.
12. Marx RE. Platelet-rich plasma: Evidence to support its use. *J Oral Maxillofac Surg.* 2004;62:489–96.